

V. MUSCULAR SYSTEM / LOWER LIMB

MUSCLES OF THE FOOT (INTRINSICS)

CN: Feel free to use the colors used for the letter labels on plates 57 and 58. Those letters are presented here for identification, and the muscles they refer to are not meant to be colored. Also note that plantar surface attachment sites for those extrinsic foot muscles have been omitted in the illustration of the fourth layer but can be found on the two preceding plates. (1) Begin with the fourth layer and complete each illustration before going on to the next.

The dorsal intrinsic muscles of the foot (those that arise and insert within the dorsum of the foot) are limited to two *small extensors* of the toes shown at right, most of the extensor function being derived from extrinsic extensors.

The intrinsic muscles of the plantar region of the foot are shown here in four layers. The *plantar interossei*, wedged between the metatarsal bones, constitute the deepest (4th) layer. They adduct toes 3-5, flex the metatarsophalangeal (MP) joints of these toes, and contribute to extension of the interphalangeal (IP) joints of these toes through the mechanism of the extensor expansion. The *dorsal interossei* abduct toes 3-5, and facilitate the other actions of the plantar interossei.

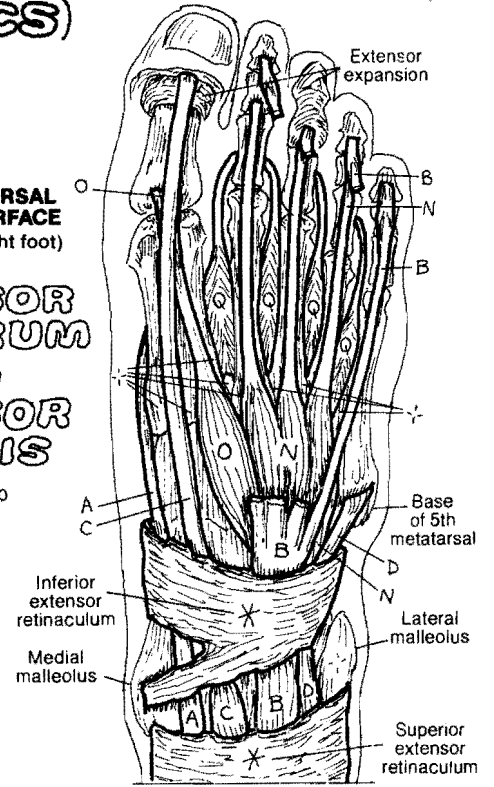
The third layer of muscles acts on the great toe (hallux) and 5th digit (digiti minimi). The second layer includes the *quadratus plantae*, inserting into the lateral border of the common tendon (H) of flexor digitorum longus (FDL). It assists that muscle in flexion of the toes. The *lumbricals* arise from the individual tendons of FDL and insert into the medial aspect of the extensor expansion (dorsal aspect). They flex the MP joints, and extend the IP joints of toes 2-5 via the extensor expansion.

The superficial (first) layer consists of the *abductors* of the 1st and 5th digits, and the *flexor digitorum brevis*. The plantar muscles are covered by the thickened deep fascia of the sole, the plantar aponeurosis, extending from calcaneus to the fibrous sheath of the flexor tendons.

EXTENSOR DIGITORUM BREVIS_N

EXTENSOR HALLUCIS BREVIS.

DORSAL SURFACE (Right foot)



3 PLANTAR INTEROSSEI,
4 DORSAL INTEROSSEI.

FLEX. HALLUCIS BREVIS_R

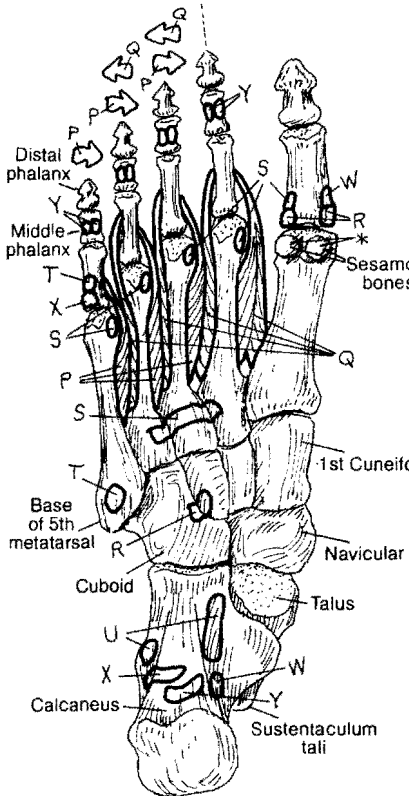
ADDUCTOR HALLUCIS_S

FLEX. DIGITI MINIMI BREV._T

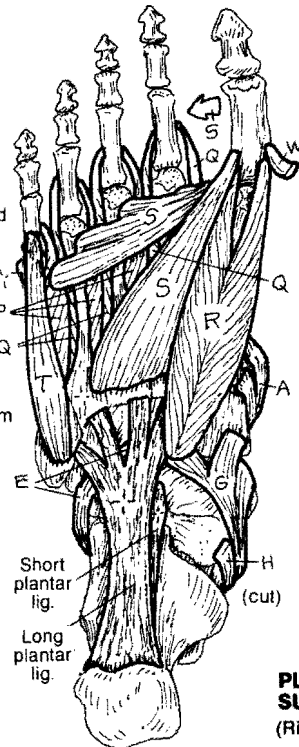
QUADRATUS PLANTAE,
4 LUMBRICALS.

ABDUCTOR HALLUCIS_W

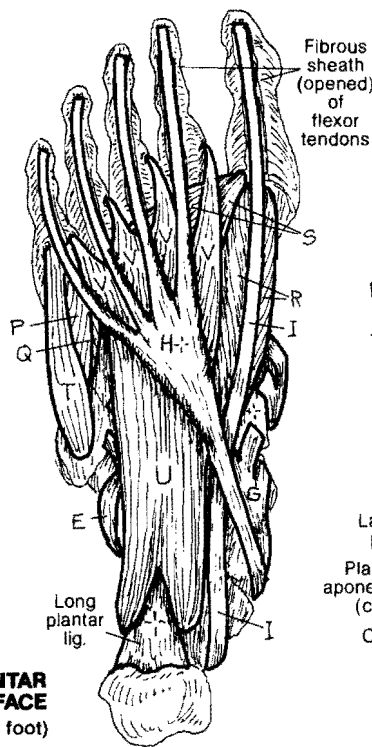
ABDUCTOR DIGITI MINIMI,
FLEX. DIGITOR. BREVIS_Y



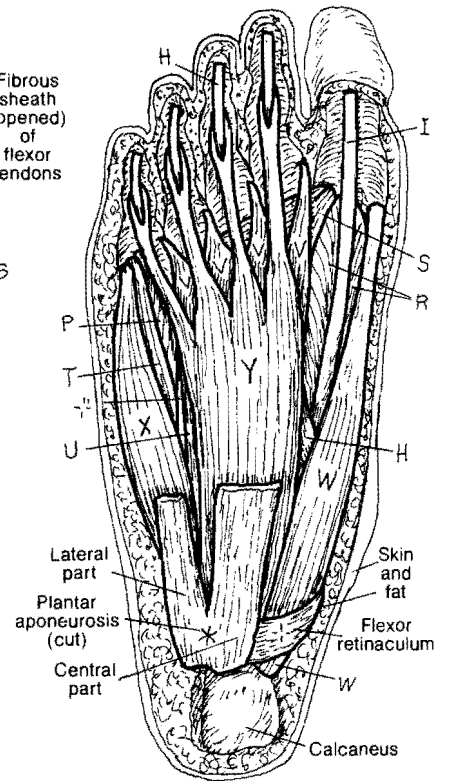
FOURTH LAYER



THIRD LAYER



SECOND LAYER



FIRST LAYER (superficial)

PLANTAR SURFACE (Right foot)